The M&B key to success:

The Implant as 'Osteotome',

Findings for our Dental Office

Many dental offices cannot function successfully because – let's face it – most patients cannot afford the CIM, the "Classical Implantology Method", including prosthodontics.

Author: Dr. Armin Nedjat

Translator: Celina Jelonek

Some 15 years ago, I found a way out of this obvious vicious circle thanks to the M&B concept (MIMI®: Minimally-Invasive Method of Implantation & BOIL: Bone – Osseocondensed – Immediately – Loaded): initially, we started with 50 implants, and by now we have over 2000 implants per year, for most of which we provide first-class prosthodontic restorations, and all this at affordable prices.

Some 95% of all cases in our dental offices can be treated successfully also without investments in equipment and material, even if the patient only has very narrow, horizontal, atrophic bone availability. For this procedure a one-piece, non self-tapping implant (e.g. Champions®- implants) is needed, which is inserted in a defined, sub-dimensioned bone cavity, condensing the bone, by applying a controlled force (40-80 Ncm).

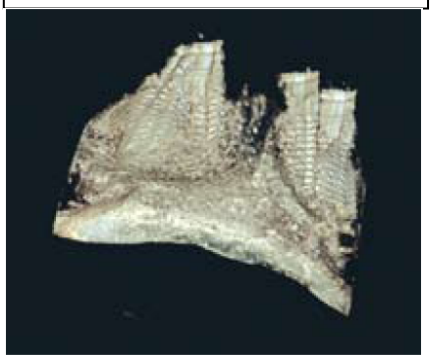

Vestibular 3 D-view of condensed Champions®: with the M&B technique, no exposed or perforated threads are noticeable even years after… Depending on the threads, the bone structures and the periost are stretched in all lateral directions. Thanks to the M&B technique, a fenestration and perforations practically never occur.

As a rule, the Champion® - implant cannot be inserted more deeply in the bone than the drilled bone cavity depth. In my opinion, small-dimensioned (< 3 mm Ø), self-tapping implants are not the right solution because as a surgeon you cannot check, for example, whether there is a perforation, which would endanger the long-term treatment success. The "critical forensic scientists" are right! No, the possibility to insert the implant in a narrow jaw does not depend on the small diameter of the implant but on the correctly drilled depth of the small bone cavity!

In the following case, the patient had contacted other dental offices before. All of them claimed that it was not possible to perform an implantation before a transplantation or augmentation of the bones in the lower jaw. The patient was told that according to the CIM, the treatment would take at least six months and that a successful treatment could naturally not be guaranteed.
One dental office had even provided the frightened patient with estimate health plan costs for four interforaminal implants, including the superstructure with the comment that his portion of 8000,-€ was a good bargain.

In fact, the patient had not been informed at all about the "M&B" concept with its minimally invasive implantation method and successful immediate loading. (Isn't the patient supposed to get comprehensive information?) After the anamnesis and the radiological and clinical results ('digital'palpation), this patient was provided with a cost health plan setting his portion of the cost at "only" 4000 euros, including all the material and laboratory costs.

However, the surgery itself was then performed as a matter of routine according to the known minimally-invasive, 'flapless' and bone condensing "M&B" concept: after the buccal and lingual infiltrations, we drilled specific sub-dimensioned bone cavities, in which we inserted the conical-shaped Champions® tulips , each with a diameter of 3,0 mm and a length of 14 mm, (choice between 16 lengths and diameters, which are also available on commission!!) with a torque of 60 Ncm, condensing the bone.

Very small flabby ridge in regio 34 -44

Drilling with the black Champions® drill in the lingual direction

View of three Champions® implants

Drilling with the black Champions® drill in the vestibular direction

Finished implantation, view from the vestibular side

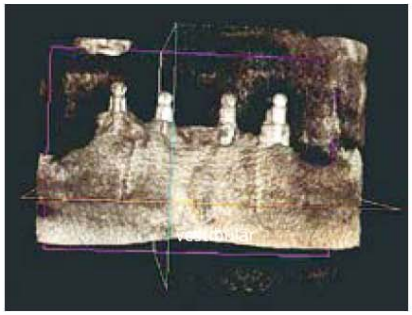

3 D - view – 3 D control shots

Due to this insertion technique as described, which is done slowly with a specific torque, perforations are excluded!

The controlled bone stretching by way of MIMI® & Boil can be seen on the 3 D – control shots, among other things.

Once it has been found that perforations in all five dimensions are excluded (bone cavity check has proven successful) after having checked the bone cavity with a bone explorer, no vestibular or lingual perforations can be caused by the implant. Instead, with the implant the peri-implant bone can be carefully 'spread', laterally condensed or 'stretched'. This is the key to success of the "M&B" concept

because this osteotomy is tolerated by the bone. Even years after, no bone recessions or fenestrations are noticeable.
The immediately, fully "osseo-integrated" implant functions rather as an osteotome than as a "classical", "curative" cylindrical two-piece implant.
The necessary primary stability and the sufficient wall strengths of the vestibular ("crucial") bone also after

Advertisement

More information?

Tel: 06 21-84 25 97-28
Fax: 06 21-84 25 97-29
service@dentaid.de
www.dentaid.de
DENTAID GmbH
Innstraße 34
68199 Mannheim

New

VITIS orthodontic

The perfect all-round treatment for patients who need it!

Competence through experience

DENTAID

Patients need an exceptional treatment – with **VITIS orthodontic,** the treatment for fixed orthopedic appliance wearers

VITIS orthodontic toothpaste and mouthwash

- **Prevents bacterial plaque formation (0,05% CPC) – keeps the appliance under hygienic conditions**
- **Re-mineralizes dental enamel (1.500 or 225 ppm NaF) – and strengthens it**
- **Regenerates the gingiva (Allantoin)**
- **Comfortable for the mucosa (Aloe Vera)**
- **Fresh, apple-mint taste**

VITIS orthodontic toothbrush with a special texture for a perfect cleaning of the brackets

VITIS orthodontic wax for protecting the mucosa from mechanical irritation

Checking the bone cavity

Shaped basal surface of the prosthesis and view of vestibular and oral "holes"

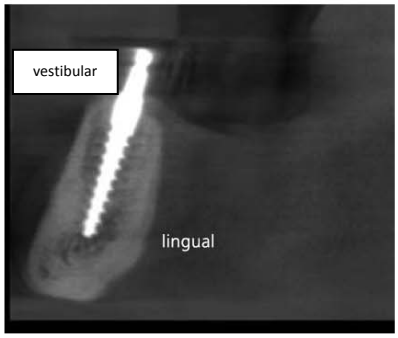

Sagittal 3D view of implant 32

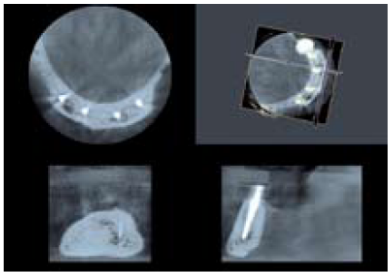

3 D - view of implant 32

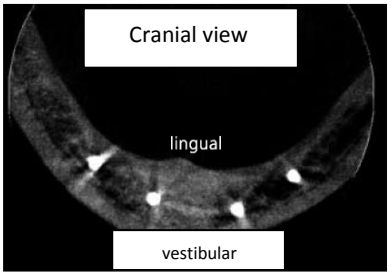

Cranial 3 D – view of the four Champions® tulips

Lingual periotest value of - 4

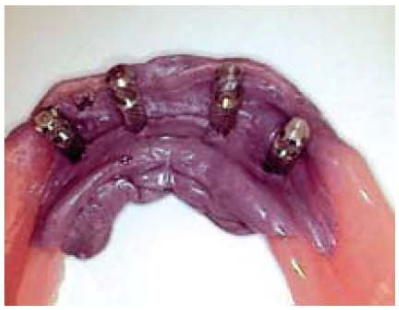

Tulip laboratory analogues are securely fixed on the Impregum impression

Metal matrices with integrated O-rings in the prosthesis

The metal matrices are very flat and leave enough room for the tongue

Exactly the same occlusion as before the implantation…

View of the mouth when inserting the prosthesis an hour after surgery

surgery guarantee a successful prosthodontic procedure with immediate loading, and this for many years or even decades…

In this case, if one had started to drill the holes in the middle of the jaw ridge, the vestibular bone lamella would have been too thin and weak, especially in the crestal area.

I also avoid “flattening” the bone plateau as one used to do it in the past so that the plateau can serve as “support” against vestibular forces. We love and desperately need our bones, and we do not want to have them unnecessarily milled!

Augmentations, long “recovery times” and pain after surgery can be prevented in most cases. After having taken an X-ray, the Impregum impression was made with the vestibular and lingual holes of the prosthesis for a fixed, closed occlusion so that the patient could bite properly with the prosthesis and also in order to prevent soft tissue tender spots. Two hours later, the extremely satisfied patient was able to leave

the dental office happily with a properly fixed prosthesis.

Our patients do not just pay for our treatment, surgery and expensive equipment in the dental office; they rather pay for our 'know-how': painless dental implantations with innovative products, and the know-how for enabling optimal, first-class prosthetic solutions in a short time. Of course, we have to prevent, recognize and respond to emergencies (e.g. Arteria lingualis!) and complications. In addition, we should be able to provide treatment according to the established CIM method as well.

The reliable long-term findings about the M&B concept are just win-win results for all participants: patients undergo painless surgery (without post surgery trauma).
The patients, who receive a quick and first-class treatment, can resume their normal daily activities one day after the surgery at the latest. Contrary to the CIM, for which the total costs payable by the patient are considered as "transit items" such as the payment for material and other outside expenditures, at least 60 – 90 % of the costs for the M&B concept remain instead as revenues in the dental office.

The M&B concept is the small, positive revolution in our dental office, which functions very well. Today, already more than 1000 dentists in Germany enjoy working according to this successful method.

Discussion?

Do you have a similar experience?

For any further questions or queries, please do not hesitate to contact champions@dental-barometer.de and write the keyword "M&B Key to Success 05_2009."

Further information

Dr. Armin Nedjat
Dentist, specialist in Implantology & Diplomate ICOI
Bornheimer Landstr. 8
D-55237 Flonheim
Telefon: +49 (0)6734 6991
Telefax: +49 (0)6734 1053
E-Mail: nedjat@t-online.de

NTI tss